

This is an open-access article distributed under the terms of the Creative Commons Attribution License, which permits unrestricted use, distribution, and reproduction in any medium, provided the original author(s) and source are credited.



ISSN: 2161-0932

Gynecology & Obstetrics

**The International Open Access
Gynecology & Obstetrics**

Executive Editors

Natalie Luzina Rasgon
Stanford University, USA

Pamela D. Berens
University of Texas - Houston Medical School, USA

S. Robert Kovac
Emory University, USA

Enrique Hernandez
Temple University, USA

Robert R. Freedman
Wayne State University, USA

Available online at: OMICS Publishing Group (www.omicsonline.org)

This article was originally published in a journal by OMICS Publishing Group, and the attached copy is provided by OMICS Publishing Group for the author's benefit and for the benefit of the author's institution, for commercial/research/educational use including without limitation use in instruction at your institution, sending it to specific colleagues that you know, and providing a copy to your institution's administrator.

All other uses, reproduction and distribution, including without limitation commercial reprints, selling or licensing copies or access, or posting on open internet sites, your personal or institution's website or repository, are requested to cite properly.

Digital Object Identifier: <http://dx.doi.org/10.4172/2161-0932.1000251>

Value of Serial Ultrasounds in Early Diagnosis and Management of Prerupture Ovarian Ectopic Pregnancy: A Case Report

Cau Van Vo^{1*}, Carol A Major² and Kamini Malhotra³

¹Department of Obstetrics and Gynecology, Division of Clinical Education, Midwestern University, Glendale, AZ 85308, Fountain Valley Regional Hospital and Medical Center, Fountain Valley, CA 92708, USA

²Department of Obstetrics and Gynecology, Maternal-Fetal Medicine Division, University of California, Irvine, CA 92868, USA

³Department of Pathology, Fountain Valley Regional Hospital and Medical Center, Fountain Valley CA 92708, USA

Abstract

Background: Primary ovarian pregnancy is a rare form of ectopic pregnancy. Even with the advance of ultrasound techniques and the sonographic establishment of fetal development, most ovarian pregnancies are found ruptured at the time of diagnosis or are a surprise finding at the time of surgery. In these cases, the associated hemorrhage is usually heavy and in approximately 23% of cases, the patients develop hypovolemic shock requiring blood transfusion.

Case: A 30-year-old female patient at 7.4 weeks by a certain LMP presented for prenatal care. An ultrasound at the time of presentation revealed no intrauterine gestational sac. There was however, a simple cystic mass contiguous with the left ovary. Subsequently, the patient had a BhCG level drawn which was not consistent with the ultrasound image and therefore was felt to be abnormal. A primary ovarian pregnancy was suspected after serial ultrasounds revealed an enlarging cystic ovarian mass and serial quantitative human Chorionic Gonadotropin (hCG) levels were abnormal. In addition, the patient started feeling left lower quadrant abdominal discomfort and reported a scant amount of vaginal bleeding. Due to the suspicion of a possible ovarian ectopic pregnancy, a diagnostic laparoscopy was discussed with the patient. The suspicion was solidified, in order to avoid rupture, a diagnostic laparoscopy was made and the ovarian ectopic pregnancy was confirmed. A wedge resection of the ovarian cyst was performed and the final histopathology confirmed a primary ovarian pregnancy.

Conclusion: Ultrasounds have been proven safe for management of obstetrical patients. The sonographic parameters for fetal development from conception to delivery have been well established and published.² At this time, ultrasound is the best tool in detecting abnormal fetal development in pregnancy. In this case, serial ultrasound examinations in the early stage of the first trimester and inappropriately rising serial BhCG levels provide the clues for detecting the prerupture diagnosis of ovarian ectopic pregnancy. The combination of these two modalities and pelvic examination increase the suspicion of a diagnosis of an ovarian pregnancy and will lead to a prompt intervention to prevent morbidity, mortality and to the preservation of future fertility.

Introduction

Primary ovarian pregnancy is an uncommon event making early diagnosis prior to its rupture very difficult. The incidence of ovarian pregnancies is estimated to be less than 1% of all ectopic pregnancies [1].

Even with the advances of ultrasound and the sonographic establishment of fetal development, most ovarian pregnancies are found to be ruptured at the time of surgery. The diagnosis is usually established after the fact, by pathological examination. Therefore, the diagnosis of an unruptured ovarian pregnancy is a big challenge for all obstetricians.

Serial ultrasounds early in the first trimester may be the most important factors contributing to the diagnosis of prerupture ovarian pregnancy. The combination of serial ultrasounds and serial serum hCG levels may lead to an accurate early diagnosis and subsequently may lead to successful minimally invasive intervention.

The following report is a case of primary unruptured ovarian pregnancy diagnosed with the use of serial ultrasounds and serial beta-hCG evaluations.

Case Report

A 30-year-old primigravid patient, presented at 7.4 weeks gestation, by her last menstrual period. The patient's medical history was unremarkable. She had no previous sexually transmitted infections or pelvic surgeries. She also had no history of dysmenorrhea and no previous complaints of any type of abdominal or pelvic pain. Her menstrual cycle was regular. At her first prenatal examination, there were no significant physical or pelvic findings.

Her initial ultrasound showed no intra-uterine gestational sac; however, there was a cystic mass (41×39 mm) with a hyperechoic ring and a lucency in the center at the left ovary (Figure 1). The hCG was subsequently ordered and the patient's initial beta-hCG level was 1,656.13 milli-international units/ml (mIU/ml) [2]. A repeat ultrasound and hCG four days later showed no significant change in the size of the cystic mass. There was however, a newly visualized light echoic area under the cyst wall. In addition, the repeat beta-hCG level was 1,714.29 mIU/ml [2]. A third ultrasound three days later demonstrated a significant increase in the echoic area and the ovarian cyst measured 59×43 mm (Figure 2) [2]. Again, there was no visualization of an intrauterine gestational sac nor was there any free fluid visualized in the cul-de-sac. At the time of this third ultrasound, the patient was experiencing mild left lower quadrant discomfort and also started having a very scant amount of vaginal spotting. This new development increased the suspicion of a possible ovarian ectopic pregnancy.

***Corresponding author:** Cau Van Vo, Department of Obstetrics and Gynecology, Division of Clinical Education, Midwestern University, Glendale, AZ 85308, Fountain Valley Regional Hospital and Medical Center, Fountain Valley, CA 92708, USA, Tel: 714-348-4782; Fax: 714-898-2105; E-mail: cauvanvo@aol.com

Received June 03, 2014; **Accepted** September 22, 2014; **Published** September 24, 2014

Citation: Vo CV, Major CA, Malhotra K (2014) Value of Serial Ultrasounds in Early Diagnosis and Management of Prerupture Ovarian Ectopic Pregnancy: A Case Report. Gynecol Obstet (Sunnyvale) 4: 251. doi:10.4172/2161-0932.1000251

Copyright: © 2014 Vo CV, et al. This is an open-access article distributed under the terms of the Creative Commons Attribution License, which permits unrestricted use, distribution, and reproduction in any medium, provided the original author and source are credited.

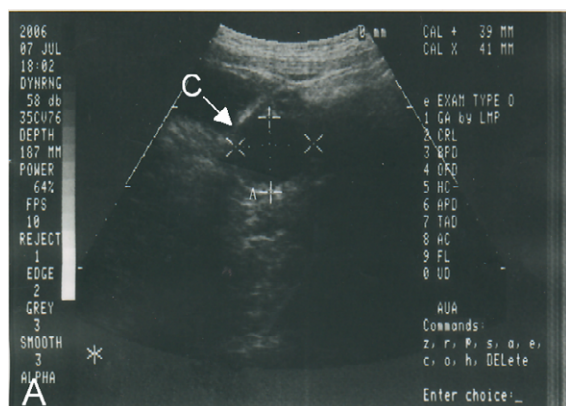


Figure 1: Sonographic image shows the intact gestational sac (C, white arrow) inside the left ovary (Figure A).

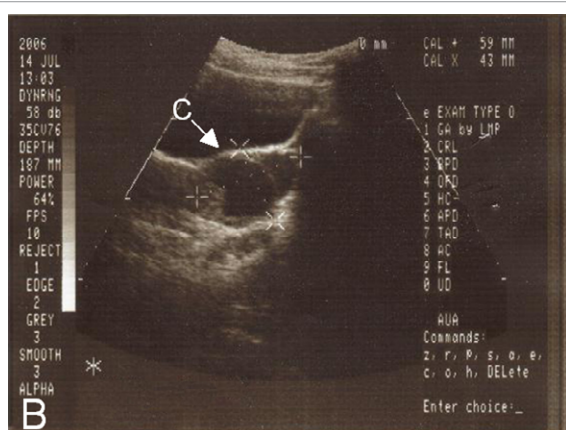


Figure 2: Sonographic image shows the intact gestational sac and the placenta (C, white arrow) inside the left ovary (Figure B).

The sonographic parameters of fetal development from conception have been well established [2]. Initially, most ovarian pregnancies would appear as a simple cyst in conjunction with an empty gestational sac [2-5]. The sac subsequently would grow larger with the wall becoming more echoic [2]. The placenta would progressively grow and form a hyperechoic structure between the gestational sac and the ovarian stroma. These changes are therefore important markers for early diagnosis of ovarian ectopic pregnancy.

In our patient, based on the ultrasonographic findings and beta-hCG levels, a diagnosis of ectopic pregnancy was suspected [3-5]. Unlike with tubal pregnancies, the ultrasound findings that we were able to visualize were strongly suggestive of an ovarian ectopic pregnancy [2,5].

A subsequent diagnostic laparoscopy revealed an unruptured left ovarian pregnancy with a purplish protrusion on the ovarian cortex (Figure 3). Both fallopian tubes appeared normal. A wedge resection of the left ovary was performed. Direct visualization of the base of the sac revealed placenta-like tissue, which was easily peeled off. A histopathological examination of the specimen confirmed the presence of chorionic villi and ovarian stroma (Figures 4-6). An endometrial curettage was also performed and revealed proliferative tissue.

The operation was performed in an outpatient surgical center. The

patient remained in the recovery room for a total of three and a half hours. Her postoperative course was uneventful and her quantitative human chorionic gonadotropin level decreased from 1,714.29 to 24.9 mIU/ml at 7 days and to 0.10 mIU/ml at 27 days postoperatively.

Comment

Primary ovarian pregnancy is an extremely uncommon form of ectopic pregnancy. Prerupture diagnosis of an ovarian pregnancy was extremely difficult before the routine use of the diagnostic ultrasound. Even with the use of diagnostic ultrasound, making a diagnosis prior to rupture has continued to be a challenge for obstetricians. The literature illustrates that ultrasonographic appearances of ovarian pregnancy vary from the presence of a simple cyst within the ovary, to the presence of a walled cystic mass or an echocomplex mass [5,6]. There has even been a rare case report documenting the presence of an ovarian cyst with a fetal pole with cardiac activity inside the cyst [2]. In another study, there were six ovarian ectopic pregnancies diagnosed by ultrasound prior to rupture. In two of these cases, the ultrasound revealed a fetal pole with cardiac activity noted within the ovary and in the other four cases, there was just a gestational sac within the ovary. The variations in these ultrasound findings have depended on the gestational age, the degree of bleeding and whether or not there has been rupture [5].

Initial ultrasonographic examination, transabdominal or

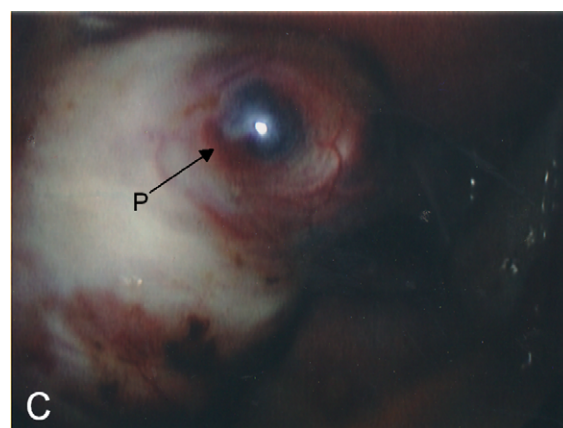


Figure 3: Laparoscopic picture demonstrates the pregnancy with purplish bulge at the intact ovarian cortex (P, black arrow) (Figure C).

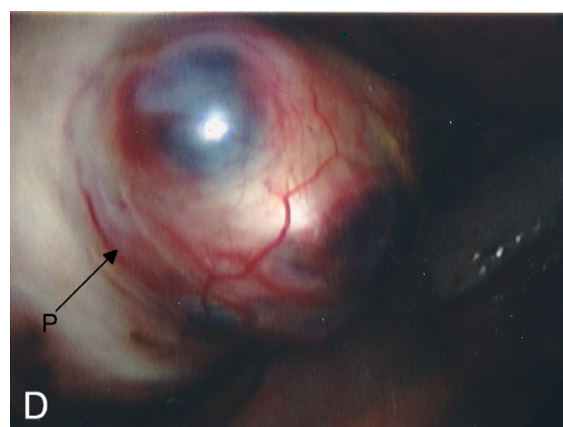


Figure 4: Laparoscopic picture shows the pregnancy inside the intact ovarian cortex (P, black arrow) (Figure D).

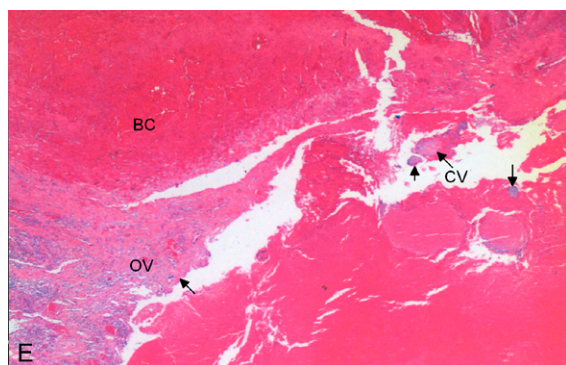


Figure 5: Histopathological examination demonstrates the chorionic villi (CV, black arrows), the ovarian stroma, (OV, black arrow), and the blood clot (BC) at low power view.

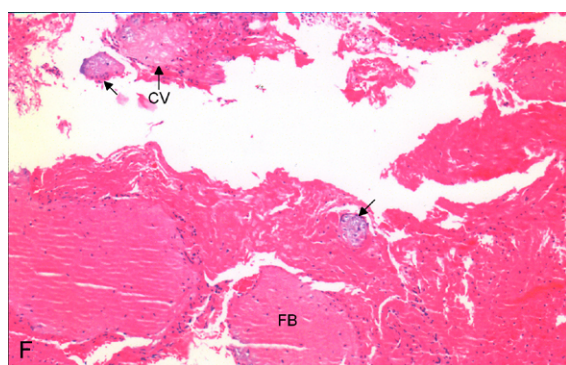


Figure 6: Histopathological examination demonstrates the degenerated chorionic villi (C V, black arrows) and fibrin (FB) at high power view.

transvaginal, can start as early as 5 weeks gestation and if the pregnancy appears to be abnormal (no gestational sac visualized within the uterus), ultrasounds can be repeated at two to three day intervals for early detection prior to rupture [2]. Several authors agreed that any patient with a beta-hCG above the discriminatory level of 1,200 mIU/ml without intrauterine gestational sac visualized was clearly presumed to have an ectopic pregnancy [3,4]. This had become a significant biochemical marker of ectopic pregnancy.

Ultrasounds have been proven safe for management of obstetric patients from conception. The sonographic parameter for development of the fetus from conception to delivery had been established and published [2]. Ovarian pregnancy is extremely rare, thus making it difficult to make an early diagnosis. Ovarian pregnancies also rupture earlier than tubal pregnancies. One study showed the mean gestational age of rupture of ovarian pregnancies was 45 days. Since ovarian pregnancies are also ectopic pregnancies, the BhCG marker for diagnosis of ectopic pregnancy could also be applied for ovarian pregnancy. The use of BhCG in aiding in the diagnosis of ectopic pregnancy has been well documented in the literature [4]. The majority of ovarian pregnancies develop as an empty sac and very few cases have had a live fetus with cardiac motion and a yolk sac.

Ultrasonographic technology had emerged as a gold standard for evaluating fetal development. Ultrasound is the best tool that can detect and differentiate between normal and abnormal development of pregnancy, especially in the early stages of the first trimester. If no intrauterine gestational sac is seen at 5 weeks by a sure LMP and there

is an inappropriately elevated BhCG, then an ectopic pregnancy should be suspected and followed closely. This is especially true if there is also an accompanying mass or cyst at the adnexa. If there is a suspicion of an ectopic pregnancy, ultrasounds should be repeated at 2-3 day intervals in an attempt to make an accurate diagnosis and to avoid possible rupture. Most ovarian pregnancy would appear sonographically as a simple cyst. This simple cyst is usually an anembryonic gestational sac [2,5]. It would initially show a smooth wall with lucency in the center. The gestational sac would subsequently grow larger at an appropriate rate during the initial weeks with the wall becoming more echogenic due to decidual reaction. The placental development also would progress and form a hyperechoic layer between the gestational sac and ovarian tissue. These changes would be a typical development of the blighted ovum and thus an important sonographic marker for early diagnosis of ovarian ectopic pregnancy. Bleeding and rupture could happen at any time leading to an immediate need for surgical intervention.

In our case, serial ultrasonographic examinations revealed significant changes in the size and the appearance of the left ovarian cystic mass. Moreover, the gestational sac size was more than 30 mm without the presence of fetal pole indicating that the ovarian cystic mass was actually a blighted ovum [2]. At the same time, serial human chorionic gonadotropin levels were not doubling in the 72-hour period. In addition, the levels of beta-hCG were above the discriminatory threshold without an accompanying intrauterine gestational sac. These were the sonographic and biochemical markers for ovarian ectopic pregnancy.

The differential diagnosis in our case included a tubal pregnancy. Our sonographic images were not typical for an unruptured tubal pregnancy since most unruptured tubal pregnancies appear as a small hyperechoic ring with a hypoechoic center surrounded by a distended tubal wall [2,5]. The differential also included an early abnormal intrauterine pregnancy with a corpus luteum cyst. In our case, the ovarian cyst was unlikely to be a corpus luteum because its appearance of the cyst was smooth and it had a thin echogenic border with an irregular fine internal echos [2]. The difficulty in differential diagnosis between ovarian and tubal pregnancy is increased after rupture because of ultrasonographic changes associated with blood clots or organized hematomas [2,5]. The sonographic images become a complex cyst or echocomplex mass.

As expected, serial ultrasound examinations in the early stage of the first trimester coupled with serial beta-hCG allowed for more unruptured ovarian pregnancies to be diagnosed preoperatively [3,4]. With the new ultrasonographic techniques, such as high resolution transvaginal ultrasound and 3-D sonography, the success in diagnosing an ectopic, before rupture, has improved significantly. This includes the diagnosis of an ovarian pregnancy [7-9].

When a diagnosis of an unruptured ovarian ectopic pregnancy is established, a quick response is necessary. The management options depend upon the clinical presentation, upon whether or not the patient is stable and upon the clinical experience of the physician. The following section describes the case studies of "methotrexate for treatment of ovarian ectopic pregnancy" in the literature from 1988 to 2014. In that time period, there were a total of 19 cases reported that were either treated with methotrexate or surgery.

Medical management

1) There were three cases, in the literature that had unruptured ovarian pregnancies that were accurately diagnosed and documented by laparoscopy (Shamma, Chelmow and Mittal). Each of these cases was successfully managed with methotrexate.

2) There were five cases of unruptured ovarian pregnancies, in the literature, that were diagnosed by ultrasounds. Three of these cases were successfully treated with systemic methotrexate (Kudo, Shamma & Patacchiola). The other two cases however, were methotrexate failures. The first of these methotrexate failures (Bagga) resulted in a continued rising of hCG after two doses of methotrexate. In this case, laparotomy was performed with a subsequent ovarian wedge resection. The second case (Panda) had abdominal pain, internal bleeding and hypovolemic shock after methotrexate administration. An emergency laparotomy was required with partial ovariectomy.

The methotrexate failures demonstrate the advantage of the use of laparoscopic direct visualization of unruptured ovarian pregnancy before initiating the methotrexate treatment. In the two of the three cases that used laparoscopic diagnosis of an unruptured ovarian pregnancy (Chelmow, Mittal), methotrexate was injected locally into the gestational sacs. There were no methotrexate failures using this method of methotrexate administration (Chelmow, Mittal) and (Pagidas) [10]. The other case of laparoscopic diagnosis was successfully treated with systemic methotrexate (Shamma). The cost is higher in this laparoscopic option with injection of methotrexate into the sac. The cost is definitely lower using systemic methotrexate with ultrasound diagnosis in comparison with surgery (Danforth). Given the fact that there were two failures in systemic methotrexate treatment (Bagga & Panda), and that, in both of those cases, the patients had favorable prognostic factors,⁹ the additional cost of the diagnostic laparoscopy may be worth it.

Surgical management

There were eleven cases, including two cases which failed in medical management, of surgical management. Among them, laparotomy was performed in four cases and laparoscopy was carried in seven cases. The postoperative courses, in all eleven cases, were reportedly uneventful. Surgical intervention was used more than methotrexate in these cases despite the fact that the medical therapy was more appealing over surgical treatment. The increased morbidity from surgery and the complications from surgery and anesthesia were cited as reasons for the medical therapy being more appealing.

Almost all authors agreed that diagnostic laparoscopy was frequently required to confirm the diagnosis of unruptured ovarian ectopic pregnancy. They also agreed that an additional benefit of diagnostic laparoscopy was the ability to simultaneously proceed with the local injection of methotrexate into the gestational sac. An accurate diagnosis of early ovarian pregnancy has been proven with advanced ultrasounds leading to more systemic methotrexate treatment; however, it is not always successful [9].

These case studies have demonstrated both successes and failures with using just an ultrasound diagnosis and systemic injection of methotrexate. They have also highlighted the reduction in cost associated with the systemic injection without the use of laparoscopy. Further large scale studies are needed to adequately evaluate the success rate of medical management of unruptured ovarian ectopic pregnancy.

Considering the difficulty in diagnosing ovarian ectopic pregnancies, most cases are usually diagnosed only at laparoscopy or laparotomy. In our case, the ultrasound findings along with the hCG levels indicated the possibility of ovarian ectopic pregnancy, in addition, the early warning symptoms of potential rupture should alert the physician to the need for an urgent surgical intervention. A laparoscopic wedge resection or cystectomy would be preferred for preserving future fertility. An oophorectomy is reserved only for

patients with a severely damaged ovary.

In 1878 Spiegelberg established four criteria for diagnosis of ovarian ectopic pregnancy:

1) The fallopian tube on the affected side must be intact, 2) the pregnancy must occupy the normal position of the ovary, 3) the affected ovary must be attached to the uterus by the ovarian ligament and 4) the ovarian tissue must be attached to the pregnancy in the specimen [3,4,8].

Almost all articles in the literature referenced these criteria as a proof of confirmation of the diagnosis. Spiegelberg described these criteria in his article published in Germany in 1878. The results described in his article would be considered an abdominal pregnancy based on our knowledge now instead of an ovarian pregnancy. Furthermore, these criteria were based on macroscopic examination of the pelvis and the specimen at the time of the surgery. A microscopic confirmation of chorionic villi or trophoblast was not available back in 1878.

These extensive studies in the literature and the results of this ovarian ectopic pregnancy provide a new perspective into the difficulty of diagnosis and differentiation with other ectopic pregnancies. This revelation is also a compelling reason for modifying the Spiegelberg's criteria which could be accurately applied to all future studies.

Considering the advances in laparoscopic surgery and the availability of histopathology today, we suggest that the Spiegelberg criteria for diagnosing ovarian pregnancies be reconsidered. We would recommend the following modified criteria for a diagnosis of primary ovarian ectopic pregnancy:

- 1) Both fallopian tubes must be intact.
- 2) The ectopic pregnancy must be within or attached to the ovary.
- 3) The chorionic villi or trophoblast and ovarian tissue must be microscopically confirmed from the surgical specimen.

In order to make a final diagnosis of ovarian ectopic pregnancy, all three of the new criteria have to be met.

Conclusion

In our case of a primigravida patient at 7.4 weeks by certain LMP who presented with an ultrasound showing no intrauterine pregnancy and a left cystic ovarian mass, there was an initial concern for an ectopic pregnancy. Our patient's serial BhCG levels were low, but they were above the discriminatory level. In addition, the patient's BhCG levels did not double in a 72- hour period. The serial ultrasounds in our patient revealed significant changes in size and the appearance of the ovarian cyst. These changes were not consistent with a simple ovarian cyst. The changes were most consistent with an ovarian pregnancy. Given the ultrasound findings, along with the BhCG levels, there were significant concerns regarding a diagnosis of an ovarian pregnancy. The addition to the patient's symptoms leads to her being taken to the operating room for a diagnostic laparoscopic procedure right away.

Ultrasound is essentially the best tool that can detect ovarian ectopic pregnancy before rupture. The combination of biochemical and sonographic markers with clinical examination prompted a preoperative diagnosis before rupture and led to successful minimally invasive surgery.

Acknowledgement

The author wishes to thank Tien Tuy Vo, Ph.D., for editorial, graphic and digital art assistance.

References

1. Wittich AC (2004) Primary ovarian pregnancy after postpartum bilateral tubal ligation: a case report. *J Reprod Med* 49: 759-761.
2. Eberhard M, Goldhofer W (1991) *Ultrasound in Gynecology and Obstetrics*. Thieme Medical Publishers, Inc. New York, USA, P. 101-106.
3. Carugno J, Patel D, Mercado R (2006) Laparoscopic management of ovarian ectopic pregnancy: A case report. *The female patient* 31:16-20.
4. Nwanodi O, Khulpateea N (2006) The preoperative diagnosis of primary ovarian pregnancy. *J Natl Med Assoc* 98: 796-798.
5. Comstock C, Huston K, Lee W (2005) The ultrasonographic appearance of ovarian ectopic pregnancies. *Obstet Gynecol* 105: 42-45.
6. Ghi T, Banfi A, Marconi R, Iaco PD, Pilu G, et al. (2005) Three-dimensional sonographic diagnosis of ovarian pregnancy. *Ultrasound Obstet Gynecol* 26: 102-104.
7. Swank ML, Harken TR, Porto M (2013) Management of interstitial ectopic pregnancies with a combined intra-amniotic and systemic approach. *Obstet Gynecol* 122: 461-464.
8. Otto Spiegelberg (1878) *Zur Casuistik der Ovarialschwangerschaft* 13: 73-79.
9. Bagga R, Suri V, Verma P, Chopra S, Kalra J (2006) Failed medical management in ovarian pregnancy despite favorable prognostic factors-a case report. *Med Gen Med* 8: 35.
10. Pagidas K, Frishman G (2013) Nonsurgical management of primary ovarian pregnancy with transvaginal ultrasound-guided local administration of methotrexate. *J Minim Invasive Gynecol* 20: 252-254.

Citation: Vo CV, Major CA, Malhotra K (2014) Value of Serial Ultrasounds in Early Diagnosis and Management of Prerupture Ovarian Ectopic Pregnancy: A Case Report. *Gynecol Obstet (Sunnyvale)* 4: 251. doi:[10.4172/2161-0932.1000251](https://doi.org/10.4172/2161-0932.1000251)

Submit your next manuscript and get advantages of OMICS Group submissions

Unique features:

- User friendly/feasible website-translation of your paper to 50 world's leading languages
- Audio Version of published paper
- Digital articles to share and explore

Special features:

- 350 Open Access Journals
- 30,000 editorial team
- 21 days rapid review process
- Quality and quick editorial, review and publication processing
- Indexing at PubMed (partial), Scopus, EBSCO, Index Copernicus and Google Scholar etc
- Sharing Option: Social Networking Enabled
- Authors, Reviewers and Editors rewarded with online Scientific Credits
- Better discount for your subsequent articles

Submit your manuscript at: <http://www.omicsonline.org/submission/>

